

# Intraoperative parathyroid hormone monitoring in minimally invasive video-assisted parathyroidectomy

E. Stenner<sup>a</sup>, C. Dobrinja<sup>b</sup>, W. Micheli<sup>a</sup>, G. Trevisan<sup>b</sup>, G. Liguori<sup>b</sup>, B. Biasioli<sup>a</sup>

<sup>a</sup>Department of Laboratory Medicine – A.O.U. Ospedali Riuniti di Trieste

<sup>b</sup>Department of General Surgery, Division of Clinical Surgery, Hospital of Cattinara, University of Trieste

## Summary

**Background.** The increasing sensitivity of preoperative localization methods in combination with intraoperative parathyroid hormone (PTHIO) has led to the use of minimally invasive procedures in parathyroid surgery. In addition, it is usually accepted that a decrease in PTHIO values by more than 50% within 5 minutes after excision of hyperfunctioning parathyroid tissue can be considered as a confirmation of the adequacy of the surgical treatment.

The aim of this study was to evaluate the impact of use of PTHIO on the success rate of minimally invasive video-assisted parathyroidectomy (MIVAP).

**Methods.** From March 2005 to March 2008 a series of 13 patients with pHPT underwent MIVAP by an anterior approach in combination with preoperative ultrasound and <sup>99</sup>Tc-SestaMIBI scintigraphy and PTHIO assay (UniCel<sup>®</sup> DxI 800 Beckman Coulter, Fullerton, California, U.S.A.). Blood drawings were routinely performed before skin incision (T0), 5 minutes (T1) and 10 minutes (T2) after the excision of the adenomatous tissue. Surgery procedures were concluded when at T1 has been reached a drop in PTHIO level >50% with respect to preoperative levels. PTH, calcemia, complications, pathologic findings, length of hospital stay, operative times, timing and number of sample collection, postoperative pain and co-

smetic results, were retrospectively analyzed.

**Results.** 13 patients (10 females, 3 males); median age: 69 years old (range: 33-86); preoperative diagnosis: 12 pts (92%) with sporadic primary hyperparathyroidism (pHPT), one (8%) with pHPT in Multiple Endocrine Neoplasia type 1 (MEN1). In 11 pts (85%) a drop of PTHIO value major than 50% at T1 was observed; for one pts (8%) the drop was of 19.5% (patient in MEN1) while in one pts (8%) a rise of 83.20% was reached. In all but one pts the drop was significant in T2. Only one PTHIO was necessary after 20 minutes after excision (T3). Median operative time and hospitalization was 85 minutes (range: 32-125), and 2 days (range: 2 -5) respectively. In all pts, frozen sections and final histology showed benign disease. Morbidity was 3 (23%) transient hypocalcemia (1 symptomatic) and 1 (8%) haematoma.

**Conclusions.** Our data underline that a PTHIO reduction of more than 50%, five minutes after the resection of adenoma, is a predictor of successful surgery and becomes of fundamental importance in surgical decision making when preoperative imaging studies miss the hyperfunctioning parathyroid tissue.

**Key-words:** intraoperative parathyroid hormone, minimally invasive video-assisted parathyroidectomy, sporadic primitive hyperparathyroidism, <sup>99</sup>Tc-sestaMIBI.

## Riassunto

**Premesse.** L'aumentata sensibilità delle indagini di localizzazione preoperatoria e la disponibilità del dosaggio del paratormone con metodica intraoperatoria (PTHIO) hanno aperto la strada per l'impiego di procedure mini-invasive nella chirurgia delle paratiroidi.

Una riduzione dei livelli sierici del PTHIO superiore al 50% rispetto ai valori del prelievo basale, dopo 5 minuti dall'asportazione dell'adenoma paratiroidico, è considerata una riduzione significativa e conferma che il trattamento chirurgico sia stato adeguato.

**Metodi.** Nel periodo tra marzo 2005 a marzo 2008, 13

pazienti con pHPT sono stati sottoposti a MIVAP; preoperatoriamente è stata eseguita una ecografia del collo e una scintigrafia tiroidea con Tc99-SestaMIBI e durante l'operazione è stato dosato il PTHIO (Access2® Beckman Coulter, Fullerton, California, U.S.A.). I prelievi di sangue sono stati eseguiti immediatamente prima dell'intervento (T0), 5 minuti (T1) e 10 minuti (T2) dopo l'asportazione del presunto adenoma paratiroidico. L'intervento chirurgico è terminato quando, al tempo T1 si è registrata una diminuzione del PTHIO superiore al 50% rispetto i valori preoperatori. Il PTH, la calcemia, le complicanze post-operatorie, la durata dell'intervento e della degenza in ospedale, il numero e la tempistica dei prelievi intraoperatori, il dolore postoperatorio ed il risultato estetico, sono stati analizzati retrospettivamente.

**Risultati.** Sono stati analizzati 13 pazienti (10 femmine e 3 maschi); mediana dell'età: 69 anni (range: 33-86); diagnosi preoperatoria: 12 (92%) iperparatiroidismo primitivo di tipo sporadico e un (8%) iperparatiroidismo in Neoplasia multiendocrina di tipo 1 (MEN1).

In 11 pazienti (85%) è stato osservato un calo del valo-

re di PTHIO maggiore del 50% al T1; in un paziente (8%), invece, è stato del 19.5% in T1 e 63.9% in T2. Infine, in un paziente (8%) si è verificato un aumento dell'83.2% in T1 e un calo del 30% in T2; un'altra valutazione è stata quindi effettuata dopo 20 minuti e si è osservata una caduta significativa (-59%). La mediana del tempo operatorio medio e del periodo di degenza è stata 85 minuti (range: 32-125) e 2 giorni (range: 2-5) rispettivamente. In tutti i pazienti è stato effettuato l'esame istologico estemporaneo al congelatore e l'esame istologico definitivo ha messo in evidenza una patologia benigna.

Sono state osservate 3 (23%) ipocalcemie transitorie (solo una sintomatica) e 1 (8%) ematoma.

**Conclusioni.** I nostri dati sottolineano che una riduzione del PTHIO superiore al 50% 5 minuti dopo l'asportazione dell'adenoma paratiroidico è associata ad un trattamento chirurgico adeguato e diviene di fondamentale importanza quando le indagini di localizzazione preoperatoria falliscono l'esatta individuazione dell'adenoma e risulta quindi indispensabile accertare il successo della terapia chirurgica in tempo reale.

## Introduction

The valid operative standard for the primitive hyperparathyroidism (pHPT) has been bilateral, cervical exploration and the visualization of all parathyroid glands<sup>1</sup>. However, the increasing sensitivity of preoperative localization methods such as <sup>99</sup>Tc-sestaMIBI scanning and ultrasounds in combination with intraoperative parathyroid hormone (PTHIO) assay have led to the use of minimally invasive procedures in parathyroid surgery<sup>2-4</sup>. In particular, the short half life, less than 5 minutes<sup>5</sup>, of intact parathyroid hormone allows it to be used during surgery to confirm the removal of all hyperfunctioning parathyroid tissue and previous studies<sup>6,7</sup> have established that a reduction in the PTHIO serum levels more than 50% with respect to the basal values could be considered as a confirmation of the adequacy of the surgical treatment even if there are discordant results about the more appropriate timing of sample collection and number of samples<sup>8,9</sup>.

The aim of this study was to evaluate the performance and clinical impact of intraoperative measurements of intact parathyroid hormone (PTHIO) in conjunction with preoperative imaging and minimally invasive video-assisted parathyroidectomy (MIVAP) technique.

## Materials and Methods

### Experimental design

During the last 3 years, from 2005 to 2008, 13 patients with sporadic pHPT, diagnosed on the basis of serum calcium values, PTH values and clinical symp-

toms, undergone MIVAP procedure. Preoperative, calcemia and PTH concentrations were systematically assayed. Moreover, complete preoperative assessment (thyroid hormone serum concentrations, ultrasonography and <sup>99</sup>mTc-SestaMIBI scintigraphy to evaluate parathyroid glands, thyroid, and lymph nodes enlargement) was evaluated. In those patients who at the preoperative imaging evidenced the thyroid nodules or the suspected parathyroid disease, fine needle aspiration cytology was performed. The eligibility criteria for MIVAP were: diagnosis of single adenoma smaller than 35 mm based on preoperative localization studies without associated goiter, suspected carcinoma of the thyroid, secondary or recurrent hyperparathyroidism, previous neck surgery and previous radiation to the neck. Intact parathyroid hormone (PTH) in routine mode was assayed the day before the parathyroidectomy (basal PTH) while the PTHIO, performed on samples drawn in the operating room, were performed: before skin incision (T0), in order to avoid false increase in the PTH concentration due to the physical manipulation of the parathyroid glands during surgery, 5 minutes (T1) and 10 minutes (T2) after the excision of the parathyroid adenoma respectively. Every blood drawing was immediately transported to the laboratory, one floor below the surgical unit, which was previously informed about the day and time of operation to allow enough time for preoperative calibration and running of quality-control samples. Results were available after 15 minutes, the required incubation time, and immediately communicated to the surgical team in the operating room. Surgical procedures

**Table I.** PTHIO inter-assay and intra-assay imprecision.

	INTER-ASSAY		INTRA-ASSAY	
MEAN	57.76	472.90	57.82	470.61
SD	3.67	34.09	4.14	33.79
%CV	6.35	7.21	7.17	7.18

The assay imprecision was evaluated by testing 2 levels of controls generating a total of 20 assay, 2 replicate per assay, over 10 days. CV% = (standard deviation/mean)\*100.

were deemed complete when at time T1 a PTHIO drop of more than 50% with respect to the preoperative values was observed, while if the drop was not as expected, the surgical procedures were continued with conversion to open cervicotomy and bilateral cervical exploration until finding and removing the pathological parathyroid gland. The day after the operation we measured PTH values while the calcemia was reached 4 hours, the following four days and the seventh one after the operation. If a postoperative hypocalcemia appeared, patients would be treated with substitutive therapy with Calcium carbonate tablets and with Dihydroxycholesterol solution per os until normalization of calcium serum levels. Finally, complications, pathologic findings, postoperative pain, timing and number of sample collection, operative times, length of hospital stay and cosmetic results were retrospectively analyzed, laryngoscopy included in order to check vocal cord mobility three weeks after operation. The definition of operative success was based on eucalcemia reached for 6 months or longer after parathyroidectomy.

### Surgical technique

MIVAP procedure, first described by Miccoli et al.<sup>10-12</sup>, totally gasless, was performed through a single 20 mm skin incision in the central neck, 1-2 cm above the sternal notch. Dissection was performed under endoscopic vision, using small conventional retractors and needlescopic (2 mm) reusable instruments. The thyroid lobe was retracted medially and the adenoma was extracted after clipping its pedicle. Video-assistance was obtained using a 5 mm large 30 degree endoscope. Haemostasis of the adenoma pedicle was achieved by conventional vascular clips or by ligatures or exceptionally by a harmonic scalpel.

### PTHIO Method

Intact PTH assay, both in routine and intraoperative mode, was performed on samples collected into potassium EDTA anticoagulant tubes according to the routine and intraoperative procedure of the Access Immunoassay System Intact PTH respectively, a paramagnetic particles, chemiluminescent immunoassay for the quantitative determination of PTH levels in human serum and plasma on Access2 Beckman Coulter (Fullerton, California, U.S.A.).

The calibration, valid up to 28 days, was performed for routine and intraoperative modes using separate

calibration cards and two control levels, low and high, were double assayed before and after surgical operation. The assay imprecision was evaluated by testing 2 levels of controls generating a total of 20 assays, 2 replicate per assay, over 10 days (Table I).

The analytical range for PTH and PTHIO assays was 1 – 3500 pg/ml and 6 - 3500 pg/ml respectively; the reference interval for PTH values was 15-88 pg/ml.

Calcium serum assay was performed with Olympus AU5400 (Tokio, Japan) using the method Arsenazio III (sensitivity < 0.12 mg/dL) and the reference interval was 8.5 – 10.5 mg/dL.

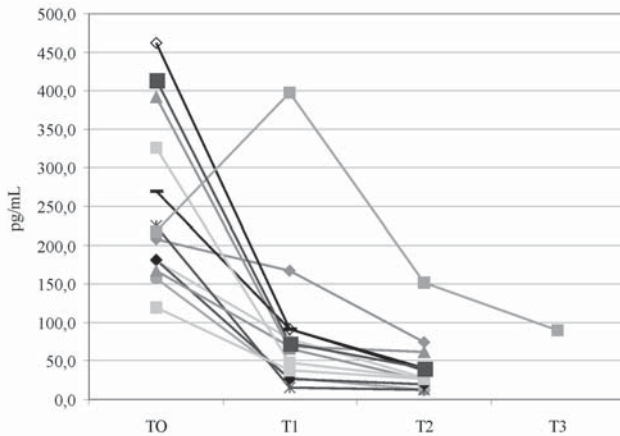
### Postoperative pain and cosmetic results

Postoperative pain was assessed in all patients by means of a visual analogue scale (VAS) according to the Joint Commission International's guidelines<sup>13</sup>. This numeric pain intensity scale consisted of a 10 cm line with the words "no pain = 0" on the left side and "worst possible pain = 10" on the right side. All patients were asked to evaluate their pain 4 and 24 hours after operation by describing its level with a number from 0 to 10. Cosmetic results evaluated in all patients with a verbal response scale. The verbal response scale had four opinions: 1 = poor, 2 = acceptable, 3 = good, 4 = excellent. The patients were asked to grade the cosmetic appearance of their wound 1 month after surgery.

### Results

MIVAP was performed in 13 patients (10 females and 3 males) with median age of 69 years old (range: 33-86). Preoperative diagnosis was 12 (92%) sporadic primary hyperparathyroidism (pHPT) and 1 (8%) pHPT Multiple Endocrine Neoplasia type 1 (MEN1). Preoperative median of calcium and PTH values was 11.00 mg/dL (range: 10.00 – 13.00) and 190 pg/mL (range: 120 – 312) respectively.

Of the 13 patients, 11 (85%) had a >50% decrease in their first post resection PTHIO values. Of the other two patients, one (8%) had a drop of 19.56% in T1 and 63.91% in T2 and the other one (8%), instead, had a rise of 83.20% in T1 and a drop of 30% in T2. Due to the fact that the drop in T2 was not >50% with respect to the T0 values, another blood drawing was performed after 20 minutes and a significant drop (-59%) was found (Fig. 1). No false negative or false



**Figure 1.** Intraoperative parathyroid hormone values during minimally invasive video-assisted parathyroidectomy (T0: pre skin incision value; T1, T2, T3: blood drawing performed after 5, 10 and 20 minutes after resection of adenomatous tissue).

positive results were reached.

The median of PTH values reached the day after the parathyroidectomy was 29.8 pg/mL (range: 9.3 – 101).

The median of calcium values, four hours after the operation was 9.58 mg/dL (range: 8.50 – 10.49) while during the following four days 3 (23%) transient hypocalcaemias, among which only 1 revealed to be symptomatic, were observed. The seventh day after the parathyroidectomy the median of the calcium values was 10.3 mg/dL (range: 8.6 – 10.6). A postoperative haematoma was observed in one patient (8%) while there were no laryngeal nerve palsies, definitive hypocalcaemias, persistent pHPT and recurrent pHPT.

Conversion to standard cervicotomy was required in one patient for ultrasound and 99mTc sestaMIBI scan false positive results.

The postoperative pain evaluated by VAS at 4 and 24 hours after operation was 1.8 (range 0 to 6). The median scare size was 2.0 cm and the cosmetic results as evaluated by bias of the verbal response were 3.6 (range 1 to 4). In all patients, frozen sections and final histology showed benign disease.

The median operative time was 85 minutes (range: 32-125) and the median hospitalization was 2 days (range: 2-5). At a mean follow-up of 15 months (range: 3-33 months), all patients were normocalcemics.

## Discussion

It is well known that, in most patients, preoperative ultrasound and 99mTc-Sestamibi scanning of the parathyroid identify the exact position and morphologic characteristics of the adenoma. Moreover, if a single adenoma, smaller than 35 mm, is diagnosed and all the other eligibility criteria, described below, are satisfied, a MIVAP technique is preferred to the conventional cervical exploration with the identification of all parathyroid glands<sup>14-17</sup>, since it permits shorter operating

and hospitalization time with respect to the conventional methods, satisfactory cosmetic results and minimized postoperative pain<sup>18</sup>. PTHIO assay is often used during MIVAP or other minimal invasive procedures to confirm the removal of hyperfunctioning parathyroid tissue even if there are discordant results about the real influence of this assay on surgical decision-making.

In our study we investigated the PTHIO values during surgical procedure and we found that all patients with a PTHIO drop of more than 50% were normocalcemics at the follow up, confirming its predictor role of surgical success<sup>7,19</sup>. Moreover, we reached a PTHIO drop lower than 50% in MEN 1 patient; in this case, in fact, a presumed parathyroid adenoma was removed and, since the PTHIO drop was not as expected, it was analyzed at the histopathologic frozen-section revealing that it was a lymph node. Consequently, the surgical procedure continued with conversion to open cervicotomy and bilateral exploration until the pathological gland, situated in the contralateral side and not indicated by the preoperative imaging studies, was found and removed.

The PTHIO increase observed in the other patient, instead, is correlated to the former removal of a tumor, that resulted to be a thyroid adenoma at frozen section, during which there was an accidental physical manipulation of the pathological parathyroid gland located immediately posterior of the removed thyroid nodule<sup>20</sup>. Consequently, the surgical procedure continued with the cervical exploration and the parathyroid adenoma was found in a different place with respect to that indicated by the preoperative imaging studies. 5 minutes after the removal of the real parathyroid adenoma, as expected, PTHIO began to drop, even if not significantly, and after 10 minutes it decreased more than 50% with respect to the pre skin incision PTHIO value.

These data underline that the PTHIO assay during parathyroidectomy adds information in surgical decision-making, leading to an additional intraoperative investigation and resection of hyperfunctioning parathyroid tissue missed by 99 Tc-SestaMIBI scanning or ultrasounds.

Regarding the postoperative complications, 3 patients (23%) exhibited a transitory hypoparathyroidism (complete recovery after an average of 3 days) but no definitive hypocalcemia, which necessitated a long life substitutive therapy, were registered. In particular, of these 3 patients, only one, with calcium serum levels as low as 8.0 mg/dL, was treated with substitutive therapy, thus reducing the rate of hypoparathyroidism necessitating therapy to 8% (1 patient).

As regards the timing of samples and the number of samples, our data suggest, in line with a previous study<sup>8</sup>, that it could be sufficient to perform only two PTHIO test during operation namely one before skin incision and one five minutes after the resection of the

adenoma. In particular, if the PTHIO drop was more than 50%, no other assay would be necessary, if the drop was not as expected, a T2 or more assays would be mandatory. However, there are discordant results about this topic<sup>8,9</sup> and further investigations are needed to optimize the timing and number of samples to improve PTHIO value-added to surgical decision making. Moreover, PTHIO assay during MIVAP would avoid a confirmation regarding the pathologic parathyroid removal by performing a frozen-section histopathologic analysis<sup>21,22</sup>, with a reduction of costs.

Finally, regarding our patients, the less surgical technique invasiveness by dropping cervicotomy length and a reduction in the cervix hyperextension during operation, minimizes postoperative pains and a satisfactory aesthetic result was obtained.

## Conclusions

In our experience, parathyroidectomy for pHPT with MIVAP combined with preoperating imaging studies and PTHIO assay during surgery is highly successful. In particular, a PTHIO drop of more than 50%, five minutes after the resection of adenoma, is a predictor of successful surgery and becomes of fundamental importance in surgical decision making when preoperative imaging studies miss the hyperfunctioning parathyroid tissue.

## Acknowledgements

The authors thank Viviana Martellani, Annalisa Gotti, Elisa Iori and Antonella Strohmayr for their technical help.

This research was supported by Beckman Coulter grants.

## References

- Delbridge LW, Younes NA, Guinea AI, Reeve TS, Clifton-Bligh P, Robinson BG. Surgery for primary hyperparathyroidism 1962-1996: indications and outcomes. *MJA* 1998; 168:153-6.
- Gagner M. Endoscopic subtotal parathyroidectomy in patients with primary hyperparathyroidism. *Br J Surg* 1996; 83:875.
- Damadi A, Harkema J, Kareti R, Saxe A. Use of pre-operative Tc99m-Sestamibi scintigraphy and intraoperative parathyroid hormone monitoring to eliminate neck exploration in mediastinal parathyroid adenocarcinoma. *J Surg Educ* 2007; 64:108-12.
- Johnson LR, Doherty G, Lairmore T, Moley JF, Brunt LM, Koenig J, et al. Evaluation of the performance and clinical impact of a rapid intraoperative parathyroid hormone assay in conjunction with preoperative imaging and concise parathyroidectomy. *Clin Chem* 2001; 47:919-25.
- Mundy GR, Guise TA. Hormonal control of calcium homeostasis. *Clin Chem* 1999; 45:1347-52.
- Sharma J, Milas M, Berber E, Mazzaglia P, Siperstein A, Weber CJ. Value of intraoperative parathyroid hormone monitoring. *Ann Surg Oncol* 2008; 15:493-8.
- Richards ML, Grant CS. Current applications of the intraoperative parathyroid hormone assay in parathyroid surgery. *Am Surg* 2007; 73:311-7.
- Barassi A, Porreca W, De Pasquale L, Bastagli A, Melzi d'Eril GV. Use of intraoperative sample to optimize efficacy of central laboratory parathyroid hormone analyses. *Clin Chem* 2007; 53:535-6.
- Di Stasio E, Carrozza C, Pio Lombardi C, Raffaelli M, Traino E, Bellantone R, et al. Parathyroidectomy monitored by intra-operative PTH: The relevance of the 20 min end-point. *Clin Biochem* 2007; 40:595-603.
- Miccoli P, Pinchera A, Cecchini G, Conte M, Bendinelli C, Vignali E, et al. Minimally invasive, video-assisted parathyroid surgery for primary hyperparathyroidism. *J Endocrinol Invest* 1997; 20:429-30.
- Miccoli P, Bendinelli C, Conte M, Pinchera A, Marocci C. Endoscopic parathyroidectomy by a gasless approach. *J Laparoendosc Adv Surg Tech A* 1998; 8:189-94.
- Miccoli P, Bendinelli C, Berti P, Vignali E, Pinchera A, Marocci C. Video-assisted versus conventional parathyroidectomy in primary hyperparathyroidism: a prospective randomized study. *Surgery* 2000; 126:1117-21.
- Frasco PE, Sprung J, Trentman TL. The Impact of the Joint Commission for Accreditation of Healthcare Organizations Pain Initiative on Perioperative Opiate Consumption and Recovery Room Length of Stay. *Anesth Analg* 2005; 100:162-8.
- Henry JF, Sebag F, Misso C, Da Costa V, Tardivet L. New surgical approaches to primary hyperparathyroidism. *Rev Med Suisse Romande* 2004; 124:93-5.
- Dralle H, Lorenz K, Nguyen-Thanh P. Minimally invasive video-assisted parathyroidectomy: selective approach to localized single gland adenoma. *Langebecks Arch Surg* 1999; 384:556-62.
- Miccoli P, Berti P, Conte M, Raffaelli M, Materazzi G. Minimally invasive video-assisted parathyroidectomy: lesson learned from 137 cases. *J Am Coll Surg* 2000; 191:613-8.
- Suzuki S, Fukushima T, Ami H, Asahi S, Takenoshita S. Video-assisted parathyroidectomy. *Biomed Pharmacother* 2002; 56(Suppl 1):18-21.
- Beyer TD, Solorzano CC, Starr F, Nilubol N, Prinz RA. Parathyroidectomy outcomes according to operative approach. *Am J Surg* 2007; 193:368-73.
- Barczynski M, Konturek A, Cichon S, Hubalewska-Dydejczk A, Golkowski Fet, Huszno B. Intraoperative parathyroid hormone assay improves outcomes of minimally invasive parathyroidectomy mainly in patients with a presumed solitary parathyroid adenoma and missing concordance of preoperative imaging. *Clin Endocrinol* 2007; 66:878-85.
- Yang GP, Levine S, Weigel RJ. A spike in parathyroid hormone during neck exploration may cause a false negative intraoperative assay result. *Arch Surg* 2001; 136:945-9.
- Saharay M, Farooqui S, Fahle-Wilson M, Brown A. Intraoperative parathyroid hormone assay for simplified localization of parathyroid adenomas. *J R Soc Med* 1996; 89:261-4.
- Romani AM, Panarese A, La Torre V, Pironi D, Sardella D, Mancini E, et al. The role of intraoperative parathyroid assay in the surgical management of hyperparathyroidism. *Ann Ital Chir* 2007; 78:91-6.